Saint Paul's Hospital Millennium Medical College Department of Forensic Medicine and Toxicology

Evaluation of the pattern of skeletal maturity of hand and wrist bone among 8 to 19 years old children from schools with known chronological age using X-rays, Addis Ababa, Ethiopia, 2022 G.C

Fekade Tesfaye (MD, Final Year Forensic Medicine and Toxicology Resident, Saint Paul's Hospital and Millennium Medical College, Addis Ababa, Ethiopia)

Addis Ababa, Ethiopia

September 2022

Saint Paul's Hospital Millennium Medical College Department of Forensic Medicine and Toxicology

Evaluation of the pattern of skeletal maturity of hand and wrist bone among 8 to 19 years old children and subadults from schools with known chronological age using X-rays, Addis Ababa, Ethiopia, 2022 G.C

By: Fekade Tesfaye (MD, Final Year Forensic Medicine and Toxicology Resident, Saint Paul's Hospital and Millennium Medical College, Gullele sub city, Addis Ababa, Ethiopia)

Advisors: Dr. Sesen Tsegaye (MD, Assistant professor of Forensic Medicine and Toxicology) and

Mr. Kinfe H. (MPH, Lecturer at Department of Public Health)

A Research Report Submitted to Department of Forensic Medicine for Partial fulfillment of Specialty Training in Forensic Medicine and Toxicology, Saint Paul's Hospital Millennium Medical College

Addis Ababa, Ethiopia

September 2022

Name of investigator	**Dr. FEKADE TESFAYE DANASO**
Full title of the research project	Evaluation of the pattern of skeletal maturity of hand and wrist bone among 8 to 19 years old children and subadults from schools with known chronological age using X-rays, Addis Ababa, Ethiopia, 2022 G.C.
Study Area	Gullele sub city, Addis Ababa, Ethiopia
Total cost of the project	31,940.00 ETB
Source of funding	St. Paul Hospital Millennium Medical College
Address of the principal investigator: Phone number Email address	Dr. Fekade Tesfaye +251949696869 fekade.tesfaye@sphmmc.edu.et
Name of advisors	Dr. Sesen Tsegaye Mr. Kinfe H.

ABSTRACT

Introduction: Because of many different factors like genetic and social or other, growth and development, chronological age could be different among children's or people of the same age. Due to this discrepancy skeletal maturation, articulated as bone age; has been recognized as significant criterion for assessing growth and development. Wrist hand bones influence in age and gender determination. The wrist hand bones play crucial part because it has more exceptional features than any other part in human anatomy. Ossifications of carpal bones, radio-ulnar bone and growth plates in between phalanges can be easily identified if x-ray of hand wrist is accessible.

Objective: To evaluate the pattern of skeletal maturity of hand and wrist among 8 to 19 years old children with known chronological age using X-rays. The degree of appearance and/or fusion of epiphyseal centers of hand wrist bones at certain age was assessed and then compared the findings of present study with other similar studies.

Methods: Community based; cross-sectional study design was conducted in schools found in Gullele sub city. Convenience sampling method was used to select study participants until 150 study subjects are found. Cross tabulation descriptive statistics method was used to analyze and compare age range with sex and stage of fusion. Chi-square test was done to observe the relation. The unpaired t-test was used to evaluate the stage of fusion between male and female. p-value <0.05 was considered as statistically significant. All the data analysis was done by using SPSS 26.0 version.

Results: The complete fusion of the epiphyses of radio-ulnar was observed 80% at the age interval of 18-19 years old students. Complete fusion of base of 1st MCB and heads of 2nd to 5th MCB was observed 80% and 100% in age group of 18-19 years. Females shows 1-2 years ahead of males in complete fusions. Pisiform bone appears from 9-11 years in females and 10-12 years in males.

Conclusions and Recommendations: Female population show delay from males in 1 – 2 years gap for the fusion bones and appearance of pisiform bone. Lower end of ulna and radius fuses completely by age of 18-19 years. But there are some variances which indicates to do the research with project and having large number sample size.

Keywords: Radiography, Bone, X-Ray, Age, Adolescents, Hand, Wrist, Medicolegal, Ethiopia

ACKNOWLEDGEMENT

My deepest gratitude goes to my research advisors; Dr. Sesen Tsegaye and Mr. Kinfe H whose guidance, genuine professional comments, and support from the beginning of the proposal to the thesis report. I'm extremely grateful for their seemingly never-ending supply of patience and support, as well as their thoughtful and detailed feedback to develop this thesis. I wish to acknowledge Dr Ferid Hamza and Dr SN Jadhav for their professional reading of all the X-ray results.

Thanks to the St. Paul's Hospital Millennium Medical College for providing me with the financial means to complete this research and the X-ray department technicians for their unfettered help. I am honored to extend my thanks to the two school directors specially Mr. Gizework of Abyssinia secondary and preparatory school for coordinating and facilitating in the recruitment of students to have X-ray imaging.

I would like to thank all participants in this study and to those who helped me and contributed directly or indirectly in this research report preparations and finalization.

TABLE OF CONTENTS

ACKNOWLEDGEMENT V

ACRONYMS AND ABBREVIATION IX

1. INTRODUCTION 1

1.1. Background 1

1.2. Statement of the problem 2

1.3. Significance of the study 2

2. LITRATURE REVIEW 4

2.1. Overview of hand and wrist bone 4

2.1.1. Carpal bone 4

2.1.2. Carpal bone 7

2.1.1. Epiphyseal plate fusion: 7

2.2. Pattern of skeletal maturity of hand and wrist bone 8

3. OBJECTIVES 12

3.1. General objective 12

3.2. Specific objective 12

4. METHODOLOGY 13

4.1. Study area and period 13

4.2. Study Design 13

4.3. Source and study population 13

4.3.1 Source population 13

4.3.2 Study population 13

4.4. Sample Size Determination: 14

4.5. Eligibility criteria 15

4.5.1 Inclusion criteria 15

4.5.2. exclusion criteria 15

4.6. Sampling technique and Sampling procedure 15
4.7. Data collection, quality, and analysis 15
4.8. Operational definitions 17
4.9. Statistical analysis 17
4.10. Ethical consideration 18
4.11. Dissemination and utilization of result 18
5. RESULTS 19
5.1. Sociodemographic characteristics of study subjects 19
5.1.1 Pattern of dentation and the age of menarche 20
5.2. Patterns of skeletal maturity of hand and wrist bone 21
5.2.1 Degree of fusion of lower end of radial bone 21
5.2.2 Patterns of lower end of ulnar bone maturity 23
5.2.3 Patterns of base of 1st metacarpal bone maturity 24
5.2.4 Patterns of heads of 2nd to 5th metacarpal bone maturity 25
5.2.5 Patterns of appearance or non-appearance of pisiform bone 26
5.3 Relationship between age range of students and degree of fusion 27
5.4 Skeletal maturity of hand wrist bone observed between males and females 28
5.4.1 Degree of fusion of epiphyses of lower radial bone among males and females 28
5.4.2 Degree of fusion of epiphyses of lower ulnar bone among males and females 29
5.4.3 Degree of fusion of epiphyses of 1st metacarpal bone among males and females 31
5.4.4 Degree of fusion of epiphyses of 2nd to 5th metacarpals among males and females .. 31
5.4.5 Appearance and non-appearance of pisiform bone among males and females 32
5.5 The difference observed between sex of participants regarding to stage of fusion 33
5 DISCUSSION 35
6 CONCLUSION and RECOMMENDATION 39

6.1 Conclusions 39
6.2 Recommendations 39
7. STRENGTH AND LIMITATIONS 40
8. REFERENCES 41
9. ANNEXES 46
9.1. Proforma - 1 46
9.2. Proforma 2: Information sheet 47
9.3. Consent form 48

ACRONYMS AND ABBREVIATION

A.A	Addis Ababa
BFM	Base of First Metacarpal bone
CT	Computed Tomography
FM	Forensic Medicine
LER	Lower end of radius
LEU	Lower end of ulnar
MCH	Meta-carpal head
MCB	Meta-Carpal Bone
mSV	milliSieVert
ROI	Region of Interest
RU	Radiology Unit
SM	Skeletal Maturity
SPHMMC	Saint Paul's Hospital Millennium Medical College
SPSS	Statistical package for Social Science
X Ray	Radiography

1. INTRODUCTION

1.1. Background

In day today medical life, age is vital for assessing the overall development of a patient. The chronological age, although easiest to determine if the child´s date of birth is known, often does not accurately reflect a patient´s development(1). "Chronological age is a key variable that has been misrepresented by demographers since a link between mortality and age was first established. Its use as a variable of choice for the analysis of all demographic phenomena which suggested that chronological age is the determinant of all demographic behaviors (2)." However, while the notion of age as the time that elapses between a person's birth and the phenomenon under study appears obvious to us today, it may encompass a number of different realities, depending on the individual, the time and the place concerned(3–5).

Because of many different factors like genetic and social or other, growth and development, and chronological age could be different among children's or people of the same age. Due to this discrepancy skeletal maturation, articulated as bone age; has been recognized as significant criterion for assessing growth and development (6,7).

The assessment of an individual's development by investigating the skeletal maturity is a very common current medical practice. There are too many methods that precisely reveal the different developmental stages. These methods work by determining the dental age and skeletal age(8). Skeletal maturity can be estimated by evaluating the morphology of the cervical vertebrae. Hand wrist radiographs have been used to estimate bone maturity, even though skeletal age determination technique is far better technique (9).

Radiographic methods are customarily used for bone age determination. For age determination purpose, hand-wrist radiographs taken from patients are commonly ideal techniques(7,9,10). Due to the possible side effects and damages of X-rays, radiation-free diagnostic methods are highly preferable. Age variation of human can be identified based on growth plates in the palms from an x ray image of hand. Initially growth plates will be thinner as the child grows to adulthood, the plates will disappear. Hand wrist x ray images are commonly used for estimation of bone age since hand can be easily exposed for minimal x-ray radiation with any position and direction, it also include many bones in single view (11).

1.2. Statement of the problem

The assessment of skeletal maturity is useful in many fields, such as pediatrics, endocrinology, pediatric dentistry, and orthodontics. In orthodontics, the degree of skeletal maturity influences the treatment planning and the optimal choice of treatment (6,12). Bone age is used for diagnosis and treatment in anthropology, cadavers, and dentistry, pediatric, orthopedic, and forensic cases in the decision-making process, and in the assessment of criminal and legal responsibility(13–16). In dentistry, especially in orthodontic treatment-planned patients, the timing of treatment and selection of the treatment method are gaining importance(17).

An increasing number of unidentified cadavers and human remains, a rise in cases requiring age determination in live individual with no valid proof of date of birth, make age assessment an important and vital tool to undertake for accurate estimation of age (3,15,16). The current educational and medical technology advancement in our continent Africa ease up the empirical age determination discrepancy during migration, law suits or medico-legal and computational sports where bone age can provide nearly accurate age information(18).

In Ethiopia people has pseudo age because of many reasons, while most children have variable physical status, developmental growth due to either nutritional, social or genetic factors. For this reason, age estimation using radiological method is vital to get the most accurate age of individuals(19–21).

Radiological examination of various ossification centers of bones form the backbone of various age determining diagnostic methodologies in the health sector(22). The hand wrist radiograph is considered to be the most standardized method of skeletal assessment. In hand wrist radiographs, the right hand is more likely to be exposed to trauma than the left hand, resulting in more reliable values using the left hand(23–26).

And therefore, the current study merely be used as a baseline to show the discrepancies between ours and other population groups using hand wrist X-ray for age determination

1.3. Significance of the study

The estimation of age is very important in medico-legal issues. Hence, it is very important, for the forensic authorities, that the age estimates are as accurate as possible. The solution of this problem is important as it is concerned to the right of legal defense of individuals.

Determining the true age of individuals is critical in medicine, ethico-legal issues, social and cultural practices as well as monitoring children's developmental status. Therefore, this study will contribute significant importance to all sectors of the society using X-ray methods of age determination technique.

Currently in Ethiopia, no single research was done on determination of age using radiographic study of bone. In the experience of clinical age determination being practiced in SPHMMC, it has been evident that those age determination methods notably derived from India has shown some gaps when it comes to interpreting the X-ray finding from Ethiopian descend. Therefore, this research will put a founding stone and it will pave a way to understand the patterns of appearance and fusion of the ossification centers of hand and wrist bone.

Additionally, conducting this study is believed to provide a valuable information on the deliverance of justice, besides to its pioneer nature of the study, it will also provide baseline findings to upcoming studies.

Furthermore, X-ray technique is not the sole means of age assessment methods rather, MRI and CT-scan has also been used for determination of age. But X-ray is preferred in this study as it has quick and easy access, very low cost, and most importantly it's routinely used in any ordinary hospital settings.

2. LITRATURE REVIEW

2.1. Overview of hand and wrist bone

Wrist hand bones influence in age and gender determination. The wrist hand bones play crucial part because it has more exceptional features than any other part in human anatomy. Ossifications of carpal bones and growth plates in between phalanges can be easily identified if digital image or x-ray of hand wrist is accessible(27).

Normal adult human anatomy includes 206 bones, on the same way hand of human body contribute more than 25% of bones. Hand bone contains 27 small bones including 8 carpals, 5 distal phalanges, 5 proximal phalanges, 4 middle phalanges and 5 metacarpals bone and therefore, identification of gender with age estimation from a hand wrist digital image is not easily accessible task(28–31).

The process of growth can be evaluated from these bones that appearance from calcification point to epiphyseal growth plates closure occurrence throughout their growth period, hence wrist bones provide a valuable means of skeleton maturity. Some of the prominent features of wrist are very important to identify gender and age at different developmental milestones(30).

2.1.1. **CARPAL BONE:** Carpal bones are primary examples to view. "Appearance of carpal bone from an infant to adulthood is a good indicator for age estimation with a difference of 4-5 months." Figure 1 and figure 2 illustrates the age of difference from an image based on carpal bone of wrist.

Fig 1; Appearance of carpal bones at age 4 years

Fig 2; Appearance of carpal bones at age 9 years

Fig 4: Epiphyseal plate fusion at age 27 years

Over decades, evaluation of bone growth was based on visual method for hand and wrist bone is commonly done using two standard methods: i) Greulich and Pyle atlas method and ii) Tanner Whitehouse method. These two methods take left hand digital images as input for prediction which is totally dependent on professional expert who checks input radiograph with standardized atlases to identify any differences if exists, later they assign evaluated score to radiograph. On an average a trained expert radiologist may take around 15 minutes for prediction of gender and age of an input image. These manual prediction techniques consume more time, and they are subject to produce differences in prediction based on the observers. Literally, the accuracy and robustness of this technique is low because of the bias in intra and inter observers since the laboratory experience plays vital role for reporting the correct estimation.

Predictions based on atlas methods need great labor effort to judge and compare radiograph for references from atlas images [1]. This process is also subjective that different evaluators judge in different approach based on their training and expertise level in this field. With the advancement in digital technology and digital imaging, many attempts were done to deploy a standard image processing method that will automatically explore key features from bone ossification that provides more efficient and effective approach in assessment of bone maturity. To the best of our knowledge, there are no standard parameters and tools reported yet that will identify gender with age by the input of hand wrist radiographs. The changes occur commonly in human bone that particularly greater during growth period. Hand bone is closely joined to the lower arm through radius and ulna bones. It is made up of metacarpal and phalange bones, 8 carpal bones all together 27 small bones. These arrangements of wrist hand bones or anatomy of bones are depicted in figure 1.

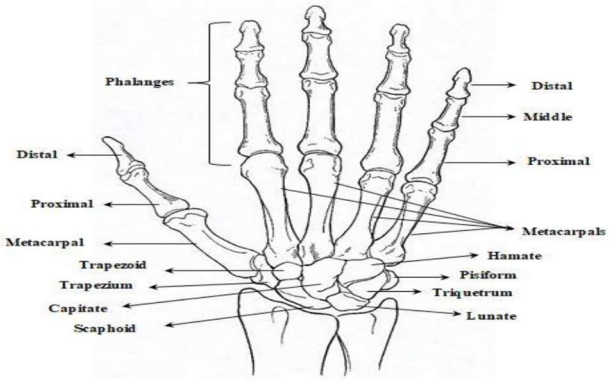

Fig 1. Anterior view of hand wrist bone

2.1.2. **CARPAL BONE:** Carpal bones are primary examples to view. "Appearance of carpal bone from an infant to adulthood is a good indicator for age estimation with a difference of 4-5 months." Figure 1 and figure 2 illustrates the age of difference from an image based on carpal bone of wrist.

Fig 2: Appearance of carpal bones at age 9 years

2.1.1. **EPIPHYSEAL PLATE FUSION:** Epiphyseal plates also known growth plates is a good indicator of maturity. Growth plate at the proximal end of metacarpal stops growing at certain age, in between 14 to 16 years old. Figure 3 and 4 depicts fusion of growth plates at different stages.

Fig 3; Epiphyseal plate fusion at age 13 years

The appearance of eight carpal wrist bones in human hand in chronological order with respect to age along with gender is depicted in table 1 below. Hamate and Capitate are the two carpal bones of the wrist that appears in newborn baby, Triquetrum bone can be visible first in a girl infant baby. Appearances of carpal bones are delayed in boys compared to girls.

Table 1: Appearance of carpal bones

Bone appeared	Carpal bone	Male	Female
First	Capitate	2.0 months	4.0 months
Second	Hamate	2.0 months	4.0 months
Third	Triquetrum	2 yrs	3 yrs
Fourth	Lunate	3 yrs	4 yrs
Fifth	Trapezium	3 yrs	4 yrs
Sixth	Trapezoid	4 yrs	6 yrs
Seventh	Scaphoid	4 yrs	6 yrs
Eighth	Pisiform	9 yrs	12 yrs

2.2. Pattern of skeletal maturity of hand and wrist bone

A study conducted in Thailand to evaluate the accuracy and reliability of Greulich–Pyle, Tanner–Whitehouse and Fishman age estimation methods (8) revealed that, the "estimated ages from the three methods were significantly different from the chronological age, except for Tanner–Whitehouse 3 RUS in males. Regarding the legal age thresholds, Greulich–Pyle (8) showed the best accuracy (83.2% for females and 79.63% for males) for legal age threshold of 10 years old. Fishman method showed the best accuracy for legal age threshold of 13 (77.5% for females and 74.31% for males) and 15 years old (83.08% for females and 73.77% for males). For age threshold of 18 years old, Greulich–Pyle showed an accuracy of 53.85% for females and 54.44% for males. The reliability tests showed substantial to almost perfect agreement"(8).

According to a critical literature review study on bone age assessment methods revealed that there is no standard method for bone age assessment. Whereas the most commonly used and extensively developed methods use Hand & Wrist radiographs in children under 18 years and computed tomography (CT) images of medial end of clavicle in individuals aged 18-22 years. Also, some methods are considered applicable to children of certain populations whereas they do not conform to the growth pattern of children in other geographic locations. The study also suggested that due to great variations in results from various bone age estimation methods, pilot studies should be carried out using various modalities, on normal healthy children and these results should be compared in order to select and/or develop the best methodology that accurately represents the growth pattern and correlates best with chronological age in Pakistani children. Subsequently, large scale researches should be planned to develop national guidelines of bone age assessment for our children (9).

According to a study conducted in India, there is insignificant difference in dental development in males and females. In this study a highly significant correlation ($P < 0.01$) was obtained between MP3 and hand-wrist in all age groups of males and females. MP3 can substitute hand-wrist radiographs for skeletal maturity evaluation. MP3 radiographs are taken on standard IOPA X-ray film. The technique has the advantages of being simple, using low patient radiation dose and exhibiting high degree of clarity of the radiographs. The equipment required is available in most dental clinics. Canine maturation shows close association with MP3 and hand-wrist in the age group 12-14 years (17).

On the other hand, the study reflected skeletal age (from MP_3 and hand-wrist) and dental age do not show high correlation regardless of the sex of the participant with chronological age in all the age groups which indicates that chronological age has no sufficient correlation with individual maturational development. The findings in this study reveal that there is highly significant correlation of MP_3 stages with hand-wrist; however, an inconsistent relationship was observed with dental age and chronological age. This suggests that MP3 radiographs can be used for assessment of skeletal age as hand-wrist radiographs. Dental and chronological ages are poor indicators of development status (17).

Another study that assessed skeletal age using hand-wrist radiographs following Bjork system showed that hand and wrist radiographic examination can give accurate bone age (skeletal age)

picture and details of the hand and wrist method introduced by Bjork which is simple and easy to use with minimal radiographs. The hand and wrist were used because it is easy to locate the different developmental stages and ossification centers which will give accurate skeletal age compared to chronological age as it is frequently accelerated or decelerated, and it is technically simple to make radiograph. The study also elaborated that every method mentioned above has its own advantages, disadvantages, and limitation over the other methods. It also concludes more research is needed to find the best method to assess the maturity of subjects seeking orthodontic treatment (32).

The study carried out between the age group of 10 to 20 years in Kavrepalanchok district of Nepal found the epiphyseal fusion at the distal end of radius and ulna to be hundred percent at the age of 18-19 years in males and 17-18 years in females. At wrist, the complete union of epiphysis is seen by 18 - 19 years in males and 16 - 17 years in females (33).

A retrospective study done on 104 girls between the age group of 16-22 years in North – Eastern region of India in 2007 shows that at the wrist joint: First degree union is found only in age group of 16 years. Second degree union is found in age group of 16 and 17 years. The third degree is found in 16 – 17 years. Fourth degree is found in 16 – 22 years (34).

The metacarpal heads appear as circular undifferentiated ossified centers until approximately 5 or 6 years of age, at which stage they begin to develop distal articular surfaces and complete fusion of the metacarpals occurs between 14 and 16 years of age (35).

A study on Bengalis observed that the ossification center of pisiform appears by 9-12 years in females and 12-17 years in males, studied the appearance of pisiform in Uttar Pradesh population on both male and female subjects and observed that it appears by 11 years in females and by 13 years in males (36).

Studied the appearance of wrist ossification centers in Australians and concluded that pisiform appears by the age of 9 years in females and by 11 years in males. (37). a study on North Karnataka observed that the ossification center of Pisiform appears by 6.-15 years in females and 12-15 years in males. The similar finding has been noticed in the present study with the appearance of pisiform ossification center by 9 to 11 years in female (i.e. one year earlier) compared to males, which appears by 10 to 12 years (38).

A retrospective radiological study done in Saudi Arabia in 2020 with 279 children shows that the pisiform bone in females starts to ossify at 7 years old but only at age group 9 in boys and it was the last bone to ossify in both gender (39).

According to a study conducted in Shaheed Hassan Khan Mewati Government Medical College, Haryana showed that skeletal age assessment is one of the most reliable methods for assessing developmental age. The correct estimation of developmental age is required by pediatric endocrinologist and pediatric orthopedic surgeon for choosing the effective treatment procedure in a child patient. The study also added that the accurate age assessment has its importance in forensics. The study identified various bone age assessment methods and emphasized the hand wrist radiography is a boon for medical science. Various methods of hand –wrist assessment has been devised, the latest being the automated systems. The study also conclude that no method of hand wrist radiography is flawless and lot of research is required in this direction to obtain a desired hand wrist radiographic technique for skeletal age assessment (40).

Another study conducted in India among a total of 240 subjects aged between 12-21 years showed that, the Risser's scores evaluated in X ray and USG findings show predominance in X-ray (68.3%) as compared to USG (38.3%) findings. Among the X-ray findings the highest score was found in the age group of 20-21 years (4.93±0.34) and lowest was in 12-13 years (1.11±0.33). In case of USG findings, the highest score was found in the age group of 20-21 years (4.11±1.02) and lowest was in 12-13 years (1.66±0.86). The regression equations for predicting the age by X-ray and USG was calculated. Among the regression equations, X-ray has higher coefficient of determination (R_2=0.84) than USG (R_2=0.44) among all the subjects irrespective of gender. The coefficient of determination was higher for females on both X-ray (R_2=0.92) and USG (R_2=0.55). The males have coefficient of regression in X-ray (R_2=0.76) and USG (R_2=0.29). The predicted mean age was observed to be close to actual age on X-ray among all the subjects. However, the predicted mean age was observed to be distant from actual age on USG among all the subjects (41).

3. OBJECTIVES

3.1. General objective

Evaluation of the pattern of skeletal maturity of hand and wrist among 8 to 19 years old children from schools with known chronological age using X-rays, Addis Ababa, Ethiopia, 2022 G.C.

3.2. Specific objective

1. To find the appearance and degree of fusion of base of 1st metacarpal bones and head of the rest metacarpal bone among school children, Addis Ababa, Ethiopia, 2022 G.C.

2. To find the appearance and degree of fusion of epiphyseal centers of distal end of ulna and radius among school children, Addis Ababa, Ethiopia, 2022 G.C.

3. To find the appearance and/or nonappearance of the pisiform bone among school children and, Addis Ababa, Ethiopia, 2022 G.C.

4. Compare and contrast the degree of skeletal maturity observed between male and females at different chronological age among school children, Addis Ababa, Ethiopia, 2022 G.C.

4. METHODOLOGY

4.1. Study area and period

The study was conducted at Gullele sub-city which is among the 11 sub cities in Addis Ababa city administration, between May 2022 and October 2022. The sub city has a total population of 284,865 with male 137,692 and woman 147,173(CSA,2007). The site of the study, Gulele sub city has 6 government secondary school (Entoto Amba, Kechene Debre Selam, Dilber, Medhanealem, Meraf, Abyssinia and Genral Taddse Birru secondary schools) and one boarding secondary school namely Etege Menen girls boarding school administered by city administration of Addis Ababa education bureau and 12 private secondary schools. The total secondary school student enrolled in the sub city both public and private on 2020/2021 academic calendar is 16904 of which male 7792 and female 9112, thus total student evolved in government secondary school is 12375. Three classes from elementary school and three classes from elementary school of *Ediget Ber* and high school of *Abyssinia* school was selected as a study area. This is because of resource constraint related to radiation cost and its proximity to Saint Paul's hospital millennium medical college, where the radiography diagnosis was taken place. (40)

4.2. Study Design

Analytical, community based, cross-sectional study was conducted whereby data was collected from the study subjects using radiology (X-Ray) of the non-dominant hand.

4.3. Source and study population

4.3.1 SOURCE POPULATION

All healthy children aged 8-19 years old students enrolled to *Abyssinia* and *Ediget Ber* schools, in Gullele sub city, Addis Ababa.

.

4.3.2 STUDY POPULATION

All healthy children aged 8-19 years old students enrolled in *Abyssinia* and *Ediget Ber* schools taking three elementary classes and three high school classes in Gullele sub city, Addis Ababa, and who fulfill the inclusion criteria.

4.4. Sample Size Determination: The sample size is determined by using Single population proportion formula $\left(\frac{\left(z\alpha/_2\right)^2 p(1-p)}{d^2}\right)$ with the following assumption of 50% for no former study is conducted in the country. A 95% level of confidence, 5% margin of error and 5% non-respondent rate was used.

$$\boldsymbol{n = \frac{\left(z\alpha/_2\right)^2 p\,(1-p)}{d^2}}$$

Were

***n*=** the desired sample size**.**

Z α/2= critical value at 95% confidence level of certainty = 1.96.

P= is the proportion of radiography and ultrasonography mean value measurement = 50%.

d= marginal error of between the sample and population = 5%

$$\boldsymbol{n} = \frac{(1.96)^2 0.5(1-0.5)}{0.05^2} = \frac{0.9604}{0.0025} = \mathbf{384}$$

Then using correction formula as the total population is below 10,000

Therefore, based on the total average number of students enrolled in single classroom at *Abyssinia* secondary and preparatory school and Ediget Ber primary school is 40 in each class. So, taking 3 class from each school would bring a total of about 240 students. Since, the source population is less than 10,000 the sample size was adjusted with the following correction formula.

n= the desired sample size?

N_o = Initial total sample size (384).

N = Total population (240)

$$n = \frac{n_o}{1+(n_o/N)} = \frac{384}{1+(384/_{240})} = \frac{384}{2.6} = \mathbf{147}$$

Using 5% non-respondent rate (5), the total sample size will become =**154**

4.5. Eligibility criteria

4.5.1 INCLUSION CRITERIA

- ✓ Both the males and females between the age group of 8 to 19 years
- ✓ Subjects having proof of age (in the form of birth certificate, school records, ration card and immunization card) has been included.

4.5.2. EXCLUSION CRITERIA

- ✓ Subjects displaying any sign of disease (thyroid disfunction, rickets etc) affecting skeletal maturation.
- ✓ Subjects with history or any stigmata of previous fractures of bones (of hand wrist) and subjects who are severely malnourished have been excluded in this study.
- ✓ Female subjects who are pregnant have been excluded.

4.6. Sampling technique and Sampling procedure

All healthy adolescents aged 8-19 years old who are enrolled in the 6 classes of *Abyssinia* high school and *Ediget Ber* primary schools in Gullele sub-city will be included. For the purpose of convenience with regard to limited resource, out of the total schools, convenient sampling was used as all study participants might not have birth certificates and all study participant with birth certificates might not give consent to participate in the study because of the concern of radiation exposure. When a study subject was found to be eligible for this study but, did not gave a consent, those subjects was automatically excluded and baseline characteristic of those consenting and not consenting subjects was assessed to avoid sampling bias. Eligible and willing participants was assigned for the X-ray until I get 150 study subjects with X-ray of the hand wrist.

4.7. Data collection, quality, and analysis

The subjects were given an explanation in their understandable language about the procedure and written informed consent was taken. The consent and written informed sheet were translated to Amharic and Oromiffa for the study subject and parents to read and sign upon consenting. Regarding children from school consent was taken from the principal of the respective school. The

data regarding students' particulars like age, sex, clinical history etc. was taken on predesigned proforma.

Detailed physical examination was done. The radiography in the form of X-rays was done. Visualization by hand & wrist plain film radiographs using standard posteroanterior (PA) view of the hand and wrist was taken. The effective radiation received during each exposure was between 0.0001-0.1 mSV (44). Typically, left-hand radiographs were utilized (as most individuals are right dominant and the left hand has less chance of being deformed). The study subjects were asked to lie down their left-hand prone position for X-ray. Adequate precautions were taken to avoid unnecessary X-ray exposure of subjects and as well for the working staffs.

The radiographic staging of X-rays scan of individual subject was evaluated with respect to the stage of epiphyseal ossification by a senior forensic physician in collaboration with radiologists. Therefore, the assessors were assigned as one from forensic senior physician and another from radiologist. Each of assessors have blindly (without knowing the chronological age of the study subjects) evaluated the hand wrist bone skeletal maturity of the study subjects by using McKern and Stewart (1957) assessment method. When there is a disagreement between those assessors regarding on assessed age, a third assessors from forensic senior had made an assessment on the degree of maturity. The X-rays were assessed as appearance and nonappearance of epiphysis and different phases of skeletal maturity were graded according to McKern and Stewart (1957) (44). Classification on epiphyseal union (stage of fusion) which subdivides the continuum of epiphyseal union into five stages is shown on Table 4.1 below:

Table 4.1: Classification on epiphyseal union

Stage	**Description**
Stage 1	Nonunion – when the epiphyseal cartilage did not begin to decrease in thickness
Stage 2	Commence of union – when the thickness of epiphysial cartilage was found to be reduced appreciably (1/4th united)

Stage 3	Incomplete union – when the epiphysis has begun to fuse with shaft and complete union was well underway (1/2 united)
Stage 4	Complete union – when the epiphyseal cartilage was bony in architecture and its density indistinguishable from the epiphysis and diaphysis in its neighborhood but an epiphysial line called epiphysial scar could still be distinguished. (3/4 united)
Stage 5	Complete union – with absence of epiphyseal scar

Zero (0) was designated for the appearance of bone and not appearing was indicated when the epiphyseal end has not appeared at all.

4.8. Operational definitions

1. **Appearance**: If the ossification center has appeared and visible on plain radiography.
2. **Non-appearance**: If the ossification center of interest doesn't appear or exist on viewing plain radiography.
3. **Non fusion**: Includes all ossification centers where the epiphysis has appeared but does not yet start fusing or fused completely. It includes stage 1 to stage 2 of epiphyseal union.
4. **Partial fusion**: Where the epiphysis of the bone has started fusion but not into phase of completed fusion. Epiphyseal scar can be present and includes stage 3 and 4 of epiphyseal union.
5. **Completed fusion**: where the epiphysis of the bone has completely fused, and no epiphyseal scar is visible, and it includes stage 5.

4.9. Statistical analysis

Results were presented in tables, graphs, scatter plot and narrations. Cross tabulation descriptive statistics method was used to analyze and compare age range with sex and stage of fusion. Chi-square test was done to observe the relation. The unpaired t-test was used to evaluate the predicted stage of fusion between male and female. p-value <0.05 was considered to be statistically

significant. Inter-observer difference and the percentage was calculated and assessed regarding reading of the X-rays and for that Kappa statistics was calculated to know the agreement and disagreement between the two assessors. The data ware entered, cleaned, and coded in Microsoft Excel and transferred and analyzed through Statistical Package for the Social Sciences (SPSS) Statistics for Windows, version 26.0.

4.10. Ethical consideration

Ethical clearance was obtained from institutional review board of SPHMMC, Research Internal Review Board (IRB) committee. Support letter from department of forensic medicine was written to SPHMMC radiology and schools. Informed written consent was obtained from all study participants from their parents or legal guardian. Participants and/or parents were informed about the objective of the study, the possible risks and benefits of participating in the study.

After information is provided about purpose of the study, non- invasiveness of the data collection procedure, confidentiality of the information and respondents was reassured that they would be anonymous (unnamed). Then respondents were given a chance to ask anything about the study and were free to refuse or stop at any moment they want if their choice.

4.11. Dissemination and utilization of result

Since the primary objective of this thesis is for partial fulfillment of specialty training in Forensic Medicine and Toxicology; it will be presented and submitted to SPHMMC department of Forensic Medicine and Toxicology. In addition, copies of the result will be given to SPHMMC pediatrics and radiology unit to utilize the information for further development of strategic and educational plan promotion. Presentations at professional, local, national and international meetings and publication in peer reviewed national or international journals will be attempted.

5. RESULTS

5.1. Sociodemographic characteristics of study subjects

In this study a total of 150 students from Abyssinia secondary and preparatory school and Ediget Ber elementary school were included.

The mean age of the students was 14.87+/-2.5 ranging from 8 -19 years old. Majority 34(22.7%) of the participants were aged 14-15 years old followed by 22(14.7%) aged 13-14 years old while as few as 3(2%) and 5(3.3%) were aged 8-9 years old and 18-19 years old respectively. Regarding sex of the participants more than half 81(54%) of the students were males while the remaining 69(46%) were females as shown in table 5.1 below.

Table 5.1 Sociodemographic distribution among age and sex

Variables	Category	Frequency			Percentage within age range		
		M	F	Total	M	F	%age from total population
Age	8-9	1	2	3	33.3%	66.7%	2%
	9-10	3	3	6	50%	50%	4%
	10-11	7	4	11	63.6%	36.4%	7.3%
	11-12	7	2	9	77.8%	22.2%	6%
	12-13	5	1	6	83.3%	16.7%	4%
	13-14	18	4	22	81.8%	18.2%	14. 7%
	14-15	16	18	34	47.1%	52.9%	22.7%
	15-16	9	9	18	50%	50%	12%
	16-17	4	7	11	36.4%	63.6%	7.3%
	17-18	10	15	25	40%	60%	16.7%
	18-19	1	4	5	20%	80%	3.3%
	Total	81	69	150	54%	46%	100%

5.1.1 Pattern of dentation and the age of menarche

Variables	Category	Teeth count								
		23	24	26	27	28	29	30	32	Total
Age	8-9	0	3	0	0	0	0	0	0	3
	9-10	0	6	0	0	0	0	0	0	6
	10-11	1	10	0	0	0	0	0	0	11
	11-12	0	8	0	0	1	0	0	0	9
	12-13	0	2	0	0	4	0	0	0	6
	13-14	0	0	2	1	19	0	0	0	22
	14-15	0	0	0	1	31	0	1	1	34
	15-16	0	0	0	0	15	0	2	1	18
	16-17	0	0	0	0	3	2	4	2	11
	17-18	0	0	0	0	9	0	2	14	25
	18-19	0	0	0	0	0	0	0	5	5
	Total	1	29	2	2	82	2	9	23	150

Most of the study participant are in the age group of 14-15 years and 20.6% of them have a total of 28 teeth followed by 12.6% and 10% at the age interval of 13-14 and 15-16 years respectively. The minimum age interval for the observed count of 28 teeth is at 11-12 years old and the maximum is between 17-18 years old. A total of 24 teeth count (mixed dentition) was observed between 8-12 years of age with maximum number (6.6%) at 10-11 years of age interval. Completion of all third molar teeth was observed between 14-19 years old with maximum number (9.3%) being at the age group of 17-18 years old. A total of 30 teeth count was observed between 14-17 years range of the total study participant with the maximum number (2.6%) being at 16-17 years of age (as shown on the table above).

Regards to the age of menarche in female study participants, 18.8% of them who has not started menses were observed between the age interval of 8-13 years. In most of females (30%), menarche started at the age 13 years followed by the age of 14 years which accounts to 27.5%. The least age to have menarche was at the age 11 years old and the maximum age was at 15 years old (as shown the table below).

Variables	Category	Age of menarche						
		Menses not started	11	12	13	14	15	Total
Age	8-9	2	0	0	0	0	0	2
	9-10	3	0	0	0	0	0	3
	10-11	4	0	0	0	0	0	4
	11-12	2	0	0	0	0	0	2
	12-13	1	0	0	0	0	0	1
	13-14	1	0	1	1	1	0	4
	14-15	0	0	4	5	7	0	18
	15-16	0	02	2	4	2	1	9
	16-17	0	0	2	1	2	2	7
	17-18	0	0	2	8	4	1	15
	18-19	0	0	0	1	3	0	4
	Total	13	2	11	20	19	4	69

5.2. Patterns of skeletal maturity of hand and wrist bone

The bone fusion pattern was assessed by 2 readers (raters) and there were no potential inter-observer differences concerning the evaluation of the fusion where Cohen's kappa score being k=0.73) that implies there was a substantial agreement between the two assessors

5.2.1 Degree of fusion of lower end of radial bone

In case of maturity of lower end of radial bone epiphysis, appearance of the ossification center was observed in 100% of studied participant, and among that non-fusion was observed in 100% of in the age range of 8-9 years old age of the population whereas the least observation (i.e., 2.9%) was observed in age interval of 14-15 years old.

On the other hand, partial of fusion was observed most in age range of 14-15 followed by 13-14 years old which is about 88.2% & 86.4% respectively. Whereas the completion of fusion was observed in 80% at the age interval of 18-19 years old students followed by 36% at age interval of

17-18 years old as shown the table 5.2.1 below. This age group where there is a complete fusion of the epiphyses and diaphysis in 100% of its population is taken as criteria for generalization.

Table 5.2.1 Degree of fusion of lower end of radial bone

Variables	Category	Lower end of radius					
		Non fusion		Partial fusion		Completed fusion	
		Fr	within age range(%)	Fr	within age range(%)	Fr	within age range(%)
Age in years	8-9	3	100%	-	-	-	-
	9-10	4	66.6%	2	33.3%	-	-
	10-11	6	54.5%	5	45.5%	-	-
	11-12	4	44.4%	5	55.6%	-	-
	12-13	1	16.7%	5	55.6%	-	-
	13-14	3	13.6%	19	86.4%	-	-
	14-15	1	2.9%	30	88.2%	3	8.8%
	15-16	1	5.6%	14	77.8%	3	16.7%
	16-17	-	-	9	81.8%	2	18.2%
	17-18	-	-	16	64%	9	36%
	18-19	-	-	1	20%	4	80%

5.2.2 Patterns of lower end of ulnar bone maturity

When observing the maturity of lower end of ulnar bone, in 100% of the studied population, the lower end of ulnar bone has appeared and, 100% of non-fusion was observed in age interval of 8-9 years old followed by 9-10 years old which accounts to 66.7% of the number of cases. Whereas the partial fusion was observed most in the age group of 13-14 years old (90.9%) followed by 14-15 years old students (85.3%) and the least (33.3%) was observed in the age group of 8-9 years old students. Most (80%) of the completed fusion is observed in the interval of 18-19 years old followed by 52% at the age group of 17-18 years old (Fig. 1) as shown the table 5.2.2 below.

Table 5.2.2: Patterns of skeletal maturity in lower end of ulnar bone

Variables	Category	lower end of ulnar epiphysis					
		Non fusion		Partial fusion		Completed fusion	
		Frequency	Percentage within age range	Frequency	Percentage within age range	Frequency	Percentage within age range
Age in years	8-9	3	100%	0	-	-	-
	9-10	4	66.7%	2	33.3	-	-
	10-11	5	45.5	6	54.5	-	-
	11-12	4	44.4	5	55.6	-	-
	12-13	1	16.7	5	83.3	-	-
	13-14	2	9.1	20	90.9	-	-
	14-15	1	2.9	29	85.3	4	11.8
	15-16	1	5.6	14	77.8	3	16.7
	16-17	0	-	8	72.7	3	27.3
	17-18	0	-	12	48	13	52
	18-19	0	-	1	20	4	80

Fig. 1 Fig.2

5.2.3 Patterns of base of 1st metacarpal bone maturity

Regarding to the maturity of the base of the first metacarpal bone, there was 100% appearance of the ossification but there was none fusion observed in 100% of age interval of 8-9 years old students followed by 9-10 and 11-12 years old (i.e., 66.7% each). The least age interval where non fusion was observed is between 16-17 years of age which accounts to 9.1%. In case of partial fusion, 76.5% of case was observed to be in the 15-16 years of age interval followed by 13-14 years of age (72.7%). Only one case found in the partial fusion stage in the age interval 18-19 years old which accounts 20%. In case of completed stage of fusion, among the age intervals 80% more completed fusion was seen at 18-19 years old followed by 48% at 17-18 years old students. Exceptionally one case (16.7%) showed completed fusion at age 9-10 years old as shown the table 5.2.3 below.

5.2.4 Patterns of heads of 2nd to 5th metacarpal bone maturity

In 100% of studied population heads of the 2nd to 5th metacarpal bone has appeared and in 100% of the age interval at 8-9 years old showed a stage of non-fusion followed by 9-10 years (66.7%) and no cases that showed non-fusion in ages greater than 14 years old. On the partial fusion stage, the maximum percentage (i.e., 90.9%) was observed at age 13-14 years and partial fusion observed at age interval 8-9 years and 18-19 years old. Completed fusion of the epiphysis with shaft was observed 100% at the age interval of 18-19 years old followed by 16-17 years old (81.8%) and the minimum age interval to see completed fusion is at 14-15 years old with exceptional pattern of completion of fusion seen on one case (16.7%) at 9-10 years old student as shown the table 5.2.4 below.

Table 5.2.3: pattern of skeletal maturity of base of first metacarpal bone

	Category	Base of the first metacarpal bone					
		Non fusion		Partial fusion		Completed fusion	
		Frequency	Percentage within age range	Frequency	Percentage within age range	Frequency	Percentage within age range
Age in years	8-9	3	100	-	-	-	-
	9-10	4	66.7	1	16.1	1	16.7
	10-11	7	63.6	4	36.4	0	-
	11-12	6	66.7	3	33.3	0	-
	12-13	2	33.3	4	66.7	0	-
	13-14	6	27.3	16	72.7	0	-
	14-15	3	8.8	26	76.5	5	14.7
	15-16	2	11.1	11	61.1	5	27.8
	16-17	1	9.1	5	45.5	5	45.5
	17-18	-	-	13	52	12	48
	18-19	-	-	1	20	4	80

Table 5.2.4: pattern of skeletal maturity of head of second to fifth metacarpal bone

	Category	Heads of 2nd to 5th MCB					
		Non fusion		Partial fusion		Completed fusion	
		Frequency	Percentage within age range	Frequency	Percentage within age range	Frequency	Percentage within age range
Age in years	8-9	3	100	-	-	-	-
	9-10	4	66.7	1	16.7	1	16.7
	10-11	2	18.2	9	81.8	-	-
	11-12	5	55.6	4	44.4	-	-
	12-13	1	16.7	5	83.3	-	-
	13-14	2	9.1	20	90.9	-	-
	14-15	-	-	22	64.7	12	35.3
	15-16	-	-	9	50	9	50
	16-17	-	-	2	18.2	9	81.8
	17-18	-	-	6	24	19	76
	18-19	-	-	-	-	5	100

5.2.5 Patterns of appearance or non-appearance of pisiform bone

Pisiform carpal bone has appeared in 132 cases (88%) of the studied populations and among them the minimum age to see the appearance of pisiform carpal bone was at 9-10 years old (33.3%) whereas in the remaining 18 cases (12%) of populations, pisiform did not appear. It was shown that in the age group of 8 to 9 years, pisiform did not appear in 100% of the studied population. In 100% of the study population, pisiform has appeared in age greater than 12 years. The nonappearance of pisiform bone was seen at age range of 8-12 year (12%) whereas appearance of it was observed starting from age 9-19 years old (88%). Subjects showing appearance of ossification center of pisiform gradually increase in number as the age advances as shown the table 5.2.5 below.

Table 5.2.5: pattern of skeletal maturity of pisiform bone

Variables	Category	Pisiform bone	
		Appearance	Non-appearance
Age	8-9 years old	0	3(100%)
	9-10 years old	2(33.3%)	4(66.7%)
	10-11 years old	6(50%)	6(50%)
	11-12 years old	5(50%)	5(50%)
	12-13 years old	6(100%)	0
	13-14 years old	21(100%)	0
	14-15 years old	33(100%)	0
	15-16 years old	18(100%)	0
	16-17 years old	11(100%)	0
	17-18 years old	25(100%)	0
	18-19 years old	5(100%)	0

5.3 Relationship between age range of students and degree of fusion

A Pearson chi-square (X^2) test of independence was performed to examine the relation between age range of students and the degree of fusion of hand-wrist bones. The relation between these variables were statistically significant ($p < .001$) as shown Table 5.3 below.

X^2 (1, N = 150) = 93.5, $p < .001$

Table 5.3 Chi-Square test

	LER		LEU		Base of 1st MCB		Heads of 2nd-5th MCB		Pisiform bone	
	Value/df	*p* value	Value/df	*p* value	Value/df	*p* value	Value/df	*p* value	Value/df	*p* value
Chi-square	93.53/20	< .001	100.23/20	< .001	82.61/20	< .001	128.54/20	< .001	72.3/10	< .001
Likelihood ratio	83.54/20	< .001	90.39/20	< .001	87.2/20	< .001	127.3/20	< .001	57.7/10	< .001
Linear by linear asso	59.73/1	< .001	63.91/1	< .001	56.18/1	< .001	73.3/1	< .001	48.1/1	< .001

5.4 Skeletal maturity of hand wrist bone observed between males and females

5.4.1 Degree of fusion of epiphyses of lower radial bone among males and females

In case of males, the non-fusion of the epiphyses of radius with shaft is observed in 5.3% of the male population at the age group of 15 to 16 years and in case of females, the non-fusion of the epiphyses of radius with shaft is observed in 50% of female population at the age group of 10 to 11 years. Thus, non-fusion of epiphyses of lower end of radius is seen at 8 to 9 years in more than 50% female population and 10 to 11 years in about 26.3% of male population. Partial fusion of the epiphyses of radius with shaft in males was observed in 3.3% of male population at 10-11 years whereas for females it was observed at 9-10 years in 4.4% of the female population. Most partial fusion stage was observed at 13-15 years in 49.2% of the male population and for females it was observed at 14-15 years old in 21.7% of the female population. The highest age group where partial fusion observed was at 17-18 years of female population (15.5%) and at 18-19 years for males

Variables	Category	Lower end of radius								
		Non fusion			Partial fusion			Completed fusion		
		M	F	No of case	M	F	Total	M	F	Total
Age	8-9	1(5.3%)	2(50%)	3	0	0	0	0	0	0
	9-10	3(15.8%)	1(25%)	4	0	2(4.4%)	2(1.3	0	0	0
	10-11	5(26.3%)	1(25%)	6	2(3.3%)	3(6.7%)	5(3.3	0	0	0
	11-12	4(21.1%)	0	4	3(4.9%)	2(4.4%)	5(3.3	0	0	0
	12-13	1(5.3%)	0	1	4(6.6%)	1(2.2%)	5(3.3	0	0	0
	13-14	3(15.8)	0	3	15(24.6%)	4(8.8%)	19(12.7	0	0	0
	14-15	1(5.3)	0	1	15(24.6%)	15(33.3%)	30(20	0	3(15%)	3(2
	15-16	1(5.3)	0	1	8(13.1%)	6(13.3%)	14(9.3	0	3(15%)	3(2
	16-17	0	0	0	4(6.6%)	5(11.1%)	9(6	0	2(10%)	2(1.3
	17-18	0	0	0	9(14.8%)	7(15.6%)	16(10.7	1(100%)	8(40%)	9(6
	18-19	0	0	0	1(1.6%)	0	1(0.7	0	4(20%)	4(2.7%)
	Total	19(100%)	4(100%)	23	61	45	106	1	20	21

(1.6%). Fusion of the epiphyses of radius is seen at 17 to 18 years in more than 100% males and 14 to 15 years in 15% of female population. Complete fission was first seen at age 14-15 years in females. Complete fusion of the epiphyses of radius is seen at 17 to 18 years in 100% males (Fig. 1) and 17 to 18 years in 40% females (Fig. 2) as shown on the table 5.4.1 above.

5.4.2 Degree of fusion of epiphyses of lower ulnar bone among males and females

In case of males, the non-fusion of the ulnar epiphyses with its shaft is observed in 5.9% of the male population at the age group of 15 to 16 years and in case of females, the non-fusion of the epiphyses of ulnar with shaft is observed in 25% of female population at the age group of 10 to 11 years. Thus, non-fusion of epiphyses of lower end of ulnar is seen at 8 to 9 years in more than 50% female population and 10 to 12 years in about 47% of male population. Partial fusion of the epiphyses of ulnar with shaft in males was observed least in 4.8% and most in 1.9% of male population at 10-11 years and 18-19 years respectively. In case of females, the least in 5% and the most 10% was observed in age group 9-10 and 17-18 years. Most partial fusion stage was observed at 13-14 years in 23.8% of the male population and for females it was observed at 14-15 years old in 35% of the female population. Complete fusion of the epiphyses of ulna is seen at 17 to 18 years in more than 100% males and 14 to 15 years in 16% of female population. Complete fusion of the epiphyses of ulna is seen at 17 to 18 years in 100% males (Fig. 1) and 17 to 18 years in 44% females (Fig. 2) as shown on the Table 5.4.2 below.

Table 5.4.2: Pattern of degree of fusion of lower end of ulnar epiphysis among male and female

Variables	Category	lower end of ulnar					
		Non-fusion		Partial fusion		Completed fusion	
		M	F	M	F	M	F
Age	8-9	1(5.9%)	2(50%)	0	0	0	0
	9-10	3(17.6%)	1(25%)	0	2(5%)	0	0
	10-11	4(23.5%)	1(25%)	3(4.8%)	3(7.5%)	0	0
	11-12	4(23.5%)	0	3(4.8%)	2(5%)	0	0
	12-13	1(5.9%)	0	4(6.5%)	1(2.5%)	0	0
	13-14	2(11.8%)	0	16(25.8%)	4(10%)	0	0
	14-15	1(5.9%)	0	15(24.2%)	14(35%)	0	4(16%)
	15-16	1(5.9%)	0	8(12.9%)	6(15%)	0	3(12%)
	16-17	0	0	4(6.5%)	4(10%)	0	3(12%)
	17-18	0	0	8(12.9%)	4(10%)	2(100%)	11(44%)
	18-19	0	0	1(1.6%)	0	0	4(16%)
	Total	17(100%)	4(100%)	62(100%)	40(100%)	2(100%)	24(100%)

5.4.3 Degree of fusion of epiphyses of 1st metacarpal bone among males and females

The non-fusion of the base of first metacarpal bone was observed at age interval of 15-16 years in 7.1% of male population whereas in 33.3% of female population, it was observed at 10-11 years old. Partial fusion of the base of 1st metacarpal bone was seen at age interval of 10-11 years in 3.8% of male population whereas in 3.1% of female population, it was observed at 9-10 years old. Completed fusion was observed in 100% of male population at 18-19 years old and in 16.1% of female population at 14-15 years of age as shown on the table 5.4.3 below.

Table 5.4.3: Pattern of degree of fusion of base of first MCB among male and female

Variables	Category	Base of first MCB					
		Non fusion		Partial fusion		Completed fusion	
		M	F	M	F	M	F
Age	8-9	1(3.6%)	2(33.3%)	0	0	0	0
	9-10	3(10.7%)	1(16.7%)	0	1(3.1%)	0	1(3.2%)
	10-11	5(17.9%)	2(33.3%)	2(3.8%)	2(6.3%)	0	0
	11-12	6(21.4%)	0	1(1.9%)	2(6.3%)	0	0
	12-13	2(7.1%)	0	3(5.8%)	1(3.1%)	0	0
	13-14	6(21.4%)	0	12(23.1%)	4(12.5%)	0	0
	14-15	3(10.7%)	0	13(25%)	13(40.6%)	0	5(16.1%)
	15-16	2(7.1%)	0	7(13.5%)	4(12.5%)	0	5(16.1%)
	16-17	0	1(16.7%)	4(7.7%)	1(3.1%)	0	5(16.1%)
	17-18	0	0	10(19.2%)	3(9.4%)	0	12(38.7%)
	18-19	0	0	0	1(3.1%)	1(100%)	3(9.7%)
	Total	28(100%)	6(100%)	52(100%)	32(100%)	1(100%)	31(100%)

5.4.4 Degree of fusion of epiphyses of 2nd to 5th metacarpals among males and females

The non-fusion of the heads of 2nd to 5th metacarpal bone was observed at age interval of 8-14 years in male population whereas in female population, it was observed at 8-11 years old. Partial fusion of the heads of 2nd to 5th metacarpal bone was seen at age interval of 10-11 years in 10.5% of male population whereas in 4.8% of female population, it was observed at 9-10 years old. Completed fusion was observed starting from age 14 years in both sexes and at 18-19 years in 100% of male and female population had completed fusion as shown on the table 5.4.4 below.

Table 5.4.4: Pattern of degree of fusion of heads of second to fifth MCB among male and female

Variables	Category	Heads of second to fifth MCB					
		Non fusion		Partial fusion		Completed fusion	
		M	F	M	F	M	F
Age	8-9	1(7.7%)	2(50%)	0	0	0	0
	9-10	3(23.1%)	1(25%)	0	1(4.8%)	0	1(2.3%)
	10-11	1(7.7%)	1(25%)	6(10.5%)	3(14.3%)	0	0
	11-12	5(38.5%)	0	2(3.5%)	2(9.5%)	0	0
	12-13	1(7.7%)	0	4(7%)	1(4.8%)	0	0
	13-14	2(15.4%)	0	16(28.1%)	4(19%)	0	0
	14-15	0	0	15(26.6%)	7(33.3%)	1(9.1%)	11(25%)
	15-16	0	0	8(14%)	1(4.8%)	1(9.1%)	8(18.2%)
	16-17	0	0	1(1.8%)	1(4.8%)	3(27.3%)	6(13.6%)
	17-18	0	0	5(8.8%)	1(4.8%)	5(45.5%)	14(31.8%)
	18-19	0	0	0	0	1(9.1%)	4(9.1%)
	Total	13(100%)	4(100%)	57(100%)	21(100%)	11(100%)	44(100%)

5.4.5 Appearance and non-appearance of pisiform bone among males and females

The maximum age interval for non-appearance of the pisiform bone extends to age 11-12 years in 28.6% of male population but in case of females it extends only to 10-11 years in 25% female population as shown on the table 5.4.5 below. It was observed that pisiform didn't appear at 8-9 years of age in both sexes. In case of females, pisiform bone appearance was observed in 3.1% of female population at 9-10 years whereas in males appeared in 4.5% of the male population at age group of 10-11 years old. This result indicates that, male population show delay for both pisiform bone non-appearance and appearance by 1-2 years compared to female populations. The mean age at which males show appearance of pisiform is 10+/-2 years and in case of females it is 9.5+/-1.5 years as shown on the Table 5.4.5 below.

Table 5.4.5: Pattern of appearance and nonappearance of pisiform bone among male and female

Variables	Category	Pisiform bone			
		Appearance		Non-appearance	
		Male	Female	Male	Female
Age	8-9	0	0	1(7.1%)	2(50%)
	9-10	0	2(3.1%)	3(21.4%)	1(25%)
	10-11	3 (4.5%)	3(4.6%)	4(28.6%)	1(25%)
	11-12	3 (4.5%)	2(3.1%)	4(28.6%)	0
	12-13	5 (7.5%)	1(1.5%)	0	0
	13-14	17(25.4%)	4(6.2%)	1(7.1%)	0
	14-15	15(22.4%)	18(27.7%)	1(7.1%)	0
	15-16	9(13.4%)	9(13.8%)	0	0
	16-17	4(6%)	7(10.8%)	0	0
	17-18	10(14.9%)	15(23.1%)	0	0
	18-19	1(1.5%)	4(6.2%)	0	0
Total		67(100%)	65(100%)	14(%)	4(%)

5.5 The difference observed between sex of participants regarding to stage of fusion

An unpaired t-test of independence was performed to examine the difference observed between sex of students and the degree of fusion of hand-wrist bones. The relation between these variables were statistically significant ($p = < .001$) as shown on the Table 5.5.1 below.

Based on the Levene's test variance of equality, except for LER, the mean variance of LEU, base of 1st MCB, heads of 2nd to 5th MCB and pisiform bones among males and females is statistically significant ($p = < .001$) that means there is a mean variance difference of stage of fusion for those hand wrist bones between males and females. Whereas the mean variance of LER among males and females is not statistically significant ($p = .085$), which means there is no mean variance difference of LER among male and female students as shown on the Table 5.3.6 below. Therefore, the unpaired t-test shows that there is a statistically significant difference ($p < .001$ and $p = .026$ for pisiform bone) among males and females regarding degree of fusion of hand wrist bones. There was a significant difference in degree of fusion of LER between males (M = 0.78, SD = 0.45) and females (M = 1.23, SD = 0.55); t(148) = -5.6, $p = < .001$. There was a significant difference in

degree of fusion of LEU between males (M = 0.81, SD = 0.45) and females (M = 1.3, SD = 0.58); t(128) = -5.7, *p* = < .001. There was a significant difference in degree of fusion of base of 1st MCB between males (M = 0.67, SD = 0.5) and females (M = 1.36, SD = 0.64); t(128) = -7.3, *p* = < .001 as shown on the Table 5.5.2 below.

Table 5.5.1 Illustrating Group statistics of hand wrist bone among males and females

Hand wrist bones	Sex of students	N	Mean	SD	Std. Error mean
LER	Male	81	0.7778	0.44721	0.04969
	Female	69	1.2319	0.54624	0.06576
LEU	Male	81	0.8148	0.45031	0.05003
	Female	69	1.3043	0.57661	0.06942
base of 1st MCB	Male	81	0.6667	0.50000	0.05556
	Female	69	1.3623	0.64102	0.07717
heads of 2nd to 5th MCB	Male	81	0.9753	0.54716	0.06080
	Female	69	1.5797	0.60405	0.07272
Pisiform bone	Male	81	1.1728	0.38046	0.04227
	Female	69	1.0580	0.23540	0.02834

Table 5.5.2 Independent sample t-test of hand wrist bone among males and females

Hand wrist bones	Equal variance	F	*p* value	t	df	*p* value (2-tailed)
LER	Assumed	3.01	.085	-5.598	148	< .001
	Not assumed			-5.509	131.408	< .001
LEU	Assumed	12.25	.001	-5.834	148	< .001
	Not assumed			-5.721	127.711	< .001
base of 1st MCB	Assumed	8.57	.004	-7.461	148	< .001
base of 1st MCB	Assumed	8.57	.004	-7.461	148	< .001
	Not assumed			-7.316	127.614	< .001
heads of 2nd to 5th MCB	Assumed	13.05	< .001	-6.427	148	< .001
	Not assumed			-6.377	138.687	< .001
Pisiform bone	Assumed	21.79	< .001	2.177	148	.031
	Not assumed			2.257	135.795	.026

5 DISCUSSION

In this study from a total of 150 study participants, most of 106/150 (70.7%) claimed to be in the age group of 8 to 16 years inclusive. According to the 2004 Ethiopian penal code, the above age group is labeled as young persons who will have special punishment. Accordingly, the mean age of the students was 14.87+/-2.5 ranging from 8 -19 years old and the sex of the participants was computed to be 81(54%) of the students being males while the remaining 69(46%) were females (table 5.1)

The Fusion of the epiphyses of radius completion was observed 80% at the age interval of 18-19 years old students followed by 36% at age interval of 17-18 years old as shown the (table 5.2.1). compared to a study conducted in Kashmiri Population (India), shows a consistent finding as the Kashmiri study revealed that, complete fusion of the epiphyses of radius is seen at 18 to 19 years in 100% males and 17 to 18 years in 100% females (45). Complete fusion of lower end of radius begin in 14-15 years in both sexes but comparing to a study conducted in India (45), the current finding shows a little discrepancy compared to the Indian study which explored that, in case of males, the fusion of the epiphyses of radius with shaft is observed in 20% of male population at the age group of 15 to 16 years and in case of females, the fusion of the epiphyses of radius with shaft is observed in 10% of female population at the age group of 13 to 14 years. This discrepancy may be due to the fact that difference in research methodology and sample stratification within age groups and difference in sociodemographic status of the two studies.

When observing the maturity of lower end of ulnar bone, in 100% of the studied population, the lower end of ulnar bone has appeared and, 100% of non-fusion was observed in age interval of 8-9 years old followed by 9-10 years old which accounts to 66.7% of the number of cases. Whereas the partial fusion was observed most in the age group of 13-14 years old (90.9%) followed by 14-15 years old students (85.3%) and the least (33.3%) was observed in the age group of 8-9 years old students. Most (80%) of the completed fusion is observed in the interval of 18-19 years old followed by 52% at the age group of 17-18 years old as shown the table 5.2.2 below and compared to a study conducted (46) by Galstaun for Bengal for both the sexes, M.J.S Pillia for South India, Ramji, this finding is consistent. It also has similar observation in study done Southern Nigeria

where appearance of the epiphyseal centers at the distal ulna and radius of males and females began at the age of 9–16 years (46).

Completed stage of fusion of base of first and heads of the rest of metacarpals bone is observed starting from 14-15 years and this observation is similar with study of GP American children where distal articular surfaces and complete fusion of the metacarpals occurs between 14 and 16 years of age (35).

Pisiform carpal bone has appeared in 132 cases (88%) of the studied populations and among them the minimum age to see the appearance of pisiform carpal bone was at 9-10 years old (33.3%) whereas in the remaining 18 cases (12%) of populations, pisiform did not appear. It was shown that in the age group of 8 to 9 years, pisiform did not appear in 100% of the studied population. In 100% of the study population, pisiform has appeared in age greater than 12 years. Subjects showing appearance of ossification center of pisiform gradually increase in number as the age advances (table 5.2.5). This observation is similar with a study done in North-Karnataka, India which shows no case showed appearance of pisiform by the age 8 years and the average range of age for appearance of pisiform ossification center is between 9 and 11 years as more than 90% of the subjects showed its appearance (47).

Since females grow earlier than males with a difference of 3 weeks during embryonic development, 4–6 weeks at birth and up to 2 years during puberty, at any age epiphyseal fusion is found to be advanced in females than males. The present study is also in accordance with such findings (1).

Partial fusion of the epiphyses of radius with shaft in males was observed in 3.3% of male population at 10-11 years whereas for females it was observed at 9-10 years in 4.4% of the female population. Most partial fusion stage was observed at 13-15 years in 49.2% of the male population and for females it was observed at 14-15 years old in 21.7% of the female population. The highest age group where partial fusion observed was at 17-18 years of female population (15.5%) and at 18-19 years for males (1.6%). This finding is consistent with study done in Southern Nigeria where partial fusion was observed at age 14 years. Our study indicates that complete fusion of the epiphyses of radius is seen at 17 to 18 years in 100% males and 17 to 18 years in 40% females which agrees with the result found by Hassan et al that concludes partial fusion at age 18, and

complete fusion was only visible at age 19 years. Also, it's similar with study done in Kavrepalanchok district of Nepal where epiphyseal fusion of distal end of radius and complete in 100% of 18-19 years in males and 17-18 years in females (33). However, the study done in Southern Nigeria (46) contradicts with our study showing appearance of fusion occurs between the ages of 9–16, however we observed that appearance began at age 14 and continued to 19. The differences observed may be owing to age range of the population studied. It is obvious from all the studies that age can be decided from radiographic observation of bones at joints.

Partial fusion of the epiphyses of ulnar with shaft in males was observed least in 4.8% and most in 1.9% of male population at 10-11 years and 18-19 years respectively. This finding is consistent with result of Edeye et al (10) where partial fusion of distal ulnar observed at age 17 years. In case of females, the least in 5% and the most 10% was observed in age group 9-10 and 17-18 years. Most partial fusion stage was observed at 13-14 years in 23.8% of the male population and for females it was observed at 14-15 years old in 35% of the female population. Fusion of the epiphyses of ulnar is seen at 17 to 18 years in more than 100% males and 14 to 15 years in 16% of female population. Complete fusion of the epiphyses of radius is seen at 17 to 18 years in 100% males and 17 to 18 years in 44% females. Again, similar trend was observed by Hassan et al. who expressed that the underlying phase of epiphyseal fusion at the lower end of the ulna was found between 14-15years in 10 % of the male populace and 13-14years in 10 % of the female populace inspected. Again, it shows a similar with study done in Kavrepalanchok district of Nepal where epiphyseal fusion of distal end of ulnar complete in 100% of 18-19 years in males and 17-18 years in females (33).

The maximum age interval for non-appearance of the pisiform bone extends to age 11-12 years in 28.6% of male population but in case of females it extends only to 10-11 years in 25% female population. This finding is consistent with a study done in Uttar Pradesh population on both male and female subjects and observed that it appears by 11 years in females and by 13 years in males (36). It was observed that pisiform didn't appear in 8-9 years of age in both sexes. In case of females, pisiform bone appearance was observed in 3.1% of female population at 9-10 years whereas in males appeared in 4.5% of the male population at age group of 10-11 years old. This result indicates that, male population show delay for both pisiform bone non-appearance and appearance by 1-2 years compared to female populations. The mean age at which males show appearance of pisiform is 10+/-2 years and in case of females it is 9.5+/-1.5 years. Our study is

consistent with study done in Australia and concluded that pisiform appears by the age of 9 years in females and by 11 years in males. (37) also similar with North-Karnataka, India where it puts female having earlier appearance of pisiform bone than male by 1-2-year gap(47). Furthermore, similar observation was present in study done by Pangeni R et al in Nepalese children where the appearance of pisiform ossification center by 9 to 11 years in female (i.e. one year earlier) compared to males, which appears by 10 to 12 years (38).

6 CONCLUSION and RECOMMENDATION

6.1 Conclusions

The age of fusion of the epiphysis of radius and ulna in case of 80% males is found to be 18 to 19 years and in case of 80% females, it is found to be 17 to 18 years. Pisiform bone appears in 9-10 years of age in female sexes and 10-11 years of male sexes, and it appears early in female sexes. On comparison with the ages of epiphyseal fusion given by other authors for different countries of the world these ages show great variations due to difference in geographical conditions and other factors. The standard for one population may not be applicable to another population. Hence different countries and even different states within the country, should establish their own standards through studies of normal children. In Ethiopia, many juveniles are arrested, sent to jail, and victimized of child labor with adults, for community theft, associated with sexual violence and they are subjected to torture and even sexual abuse during their tenure in jails. This has badly affected their development process, leading to their deviant behavior. Hence the standard for epiphyseal fusion of children becomes an important tool for fair trials and administration of justice in a conflict-ridden region.

The accurate or precise age of the individual cannot be stated by radiological examination, but a reasonable range of age can be arrived by considering the timing of appearance of ossification centers. Hence application of radiological procedures for assessment of age in living individuals is a reliable method. From these findings, we therefore conclude that radiographic analysis of bones at the hand wrists are a valuable alternative for evaluation of age and will be a useful tool to forensic experts.

To this date, a study like on this topic was not conducted in Ethiopia therefore, this study will be a steppingstone for future research to be done on the same area.

6.2 Recommendations

This study is conducted in a limited set up where resources were a constraint factor. Therefore, if this research is done repeated with project which enables to have adequate amount of sample size with equal stratification of individuals in each age intervals and with equal sex distributions, the results would be amazingly interesting. Therefore, we recommend doing it again with longer period of study.

7. STRENGTH AND LIMITATIONS

The strength of this study is that despite of resource constraints it has been tried to include an enough amount of study participants (150) when compared to other most studies done before. Additionally, our study's source of data was primary data which makes it accurate and more reliable. Our research has tried to observe both the appearance and fusion of epiphyseal of hand wrist bone with greater age range where it's the medicolegally significant age groups. The communication made with the schools were good that enables us to get the required sample size. There was no reported injuries or side effects following the procedure of taking x-rays. The X-rays were read by well acknowledged forensic seniors and it was cross checked for similarities and differences. Most of the X-ray film's quality were good. Those individuals who have got abnormalities during the X-ray study has been linked to the respective department for diagnosis and treatment.

The limitation of this study is that the number of cases examined, and sex distribution were not equal in each of age groups. This has impaired to perfectly compare results among different age groups and sexes. Since the study participants were students from school, there was difficulty of getting them in a convenient time for both school and X-ray department which leads to rushing and misrepresentation of the participant code but later solved with sorting it.

8. REFERENCES

1. Ağırman KT, Bilge OM, Miloğlu O. Ultrasonography in determining pubertal growth and bone age. Dentomaxillofacial Radiol. 2018;47(7).

2. De La Fuente M. Chronological age and biological age. An la Real Acad Nac Farm. 2017;83(1):106–15.

3. Wujec-Lizis I, Mucha A, Zabłocka-Oczoś S. CORRELATION of DENTAL and CHRONOLOGICAL AGE among A GROUP of 130 CHILDREN from the LOWER SILESIAN POPULATION. J Stomatol. 2020;

4. Vila-Blanco N, Carreira MJ, Varas-Quintana P, Balsa-Castro C, Tomas I. Deep Neural Networks for Chronological Age Estimation from OPG Images. IEEE Trans Med Imaging. 2020;

5. Kang S, Pai CK, Kim D. The role of chronological age, health, and basic psychological needs for older adults' travel intention. Sustain. 2019;

6. Vinet L, Zhedanov A. A 'missing' family of classical orthogonal polynomials. J Phys A Math Theor [Internet]. 2011 Feb 25;44(8):085201. Available from: http://link.springer.com/10.1007/978-3-642-23762-1

7. Rice DP, Israel RA, Feldman JJ. Skeletal maturity of youths 12-17 years, United States. Vital Heal Stat. 1976;ser11(160).

8. Benjavongkulchai S, Pittayapat P. Age estimation methods using hand and wrist radiographs in a group of contemporary Thais. Forensic Sci Int. 2018;287:218.e1-218.e8.

9. Mughal AM, Hassan N, Ahmed A. Bone age assessment methods: A critical review. Pakistan J Med Sci. 2014;30(1):211–5.

10. Singh A, Singh DK, D G P, Pant H. Estimation of Age By X-Ray Examination of Distal End of Humerus. J Evol Med Dent Sci. 2014;3(35):9286–303.

11. Reynolds MS, MacGregor DM, Alston-Knox CL, Gregory LS. Quantifying the ossification of the carpus in skeletal age estimation: Radiographic standards for Australian subadults.

Forensic Sci Int. 2019;

12. Topcuoglu H, Yanik A. International Journal of Medical and Health Sciences. Int J Occup Environ Health. 2014;2(4):301–7.

13. Güraksin GE, Uğuz H, Baykan ÖK. Bone age determination in young children (newborn to 6 years old) using support vector machines. Turkish J Electr Eng Comput Sci. 2016;

14. Kreitner KF, Schweden FJ, Riepert T, Nafe B, Thelen M. Bone age determination based on the study of the medial extremity of the clavicle. European Radiology. 1998.

15. Reddy NE, Rayan JC, Annapragada A V., Mahmood NF, Scheslinger AE, Zhang W, et al. Bone age determination using only the index finger: a novel approach using a convolutional neural network compared with human radiologists. Pediatr Radiol. 2020;

16. Reinehr T, Carlsson M, Chrysis D, Camacho-Hübner C. Adult height prediction by bone age determination in children with isolated growth hormone deficiency. Endocr Connect. 2020;

17. Bala M, Pathak A, Jain RL. Assessment of skeletal age using MP3 and hand-wrist radiographs and its correlation with dental and chronological ages in children. J Indian Soc Pedod Prev Dent. 2010;28(2):95–9.

18. Ishwarkumar S, Pillay P, Haffajee MR, Satyapal KS. Morphometric analysis of the mandible in the Durban Metropolitan population of South Africa. Folia Morphol. 2017;76(1):82–6.

19. Woldetsadik MA, Alemu T, Hobbs SH, Simon S. Providing medico-legal services to women and girl survivors of sexual violence: Perspectives of service providers in Addis Ababa, Ethiopia. Eur J Contracept Reprod Heal Care [Internet]. 2013;18:S65. Available from: http://ovidsp.ovid.com/ovidweb.cgi?T=JS&CSC=Y&NEWS=N&PAGE=fulltext&D=emed11&AN=71072004%0Ahttp://imp-primo.hosted.exlibrisgroup.com/openurl/44IMP/44IMP_services_page?sid=OVID&isbn=&issn=1362-5187&volume=18&issue=1&date=2013&title=European+Journal+of+Contr

20. Sume BW. Estimation of body height from percutaneous length of tibia in Debre Markos University students, North West Ethiopia. Egypt J Forensic Sci. 2019;

21. Woldetsadik MA, Alemu T, Hobbs SH, Simon S. Providing medico-legal services to women and girl survivors of sexual violence: Perspectives of service providers in Addis Ababa, Ethiopia. Eur J Contracept Reprod Heal Care. 2013;

22. Shedge R, Kanchan T, Kushwaha KPS, Krishan K. Ultrasonographic evaluation of the wrist and elbow joints: A pilot study to explore a non-invasive technique for age estimation. Med Sci Law. 2021;

23. Widek T, Genet P, Ehammer T, Schwark T, Urschler M, Scheurer E. Bone age estimation with the Greulich-Pyle atlas using 3T MR images of hand and wrist. Forensic Sci Int. 2021;

24. Diete V, Wabitsch M, Denzer C, Jäger H, Hauth E, Beer M, et al. Applicability of Magnetic Resonance Imaging for Bone Age Estimation in the Context of Medical Issues. RoFo Fortschritte auf dem Gebiet der Rontgenstrahlen und der Bildgeb Verfahren. 2021;

25. Matar I, Lucas T, Gregory L, Byun S, Morris S, Pather N. Quantifying the ossification of the carpus: Radiographic standards for age estimation in a New South Wales paediatric population. Forensic Sci Int Reports. 2021;

26. Ahn KS, Bae B, Jang WY, Lee JH, Oh S, Kim BH, et al. Assessment of rapidly advancing bone age during puberty on elbow radiographs using a deep neural network model. Eur Radiol. 2021;

27. Et. al. SKC. Novel approach to determine age and gender from wrist x-ray images. Turkish J Comput Math Educ. 2021;12(3):5215–29.

28. Behr B, Stadler J, Michaely HJ, Damert HG, Schneider W. MR imaging of the human hand and wrist at 7 T. Skeletal Radiol. 2009;

29. Zhao C, Zhao KD, Babb A, An KN. Biomechanics of the wrist and hand. In: Orthopaedic Biomechanics. 2012.

30. Copeland J, Byerly DW. Wrist Imaging. StatPearls. 2020.

31. Zilverschoon M, Vincken KL, Bleys RLAW. The virtual dissecting room: Creating highly detailed anatomy models for educational purposes. J Biomed Inform. 2017;

32. Hashim HA, Mansoor H, Mohamed MHH. Assessment of skeletal age using hand-wrist radiographs following Bjork system. J Int Soc Prev Community Dent. 2018;8(6):482–7.

33. Bhise SS, Chikhalkar BG, Nanandkar SD, Chavan GS. Age determination from radiological study of epiphysial appearance and union around wrist joint and hand. J Indian Acad Forensic Med. 2011;

34. Sangma W, Marak F, Singh M, Kharrubon B. Age determination in girls of north – eastern region of India. J Indian Acad Forensic Med. 2007;29(4):102–8.

35. GREULICH WW, PYLE SI. RADIOGRAPHIC ATLAS OF SKELETAL DEVELOPMENT OF THE HAND AND WRIST. Am J Med Sci. 1959;238(3):393.

36. Dalal D, Das A, Biswas S. Radiological study of ossification centres around pelvis to determine their age of appearance and fusion among Bengali population – A retrospective study. Indian J Forensic Med Toxicol. 2020;

37. Sidramappa HS, N HRM, G VKA. Radiological study of hand and wrist in the age groups 11-20 20 years in persons of North Karnataka. 2014;11(July):372–4.

38. Pangeni R, Khatri BB, Subedi N, Baral MP, Bagale D, Khanal GP. Age estimation based on appearance of pisiform bone in selected Nepalese children of Gandaki Province Nepal. J Gandaki Med Coll. 2020;

39. Al-Khater KM, Hegazi TM, Al-Thani HF, Al-Muhanna HT, Al-Hamad BW, Alhuraysi SM, et al. Time of appearance of ossification centers in carpal bones: A radiological retrospective study on Saudi children. Saudi Med J. 2020;41(9):938–46.

40. Sharma S, Sharma S, Goyal AK. Hand wrist radiograph: A Critical Review. Int J Oral Heal Dent. 2016;2(2):106.

41. Panday K, Khan I, Prakash V, Mishra PP. Assessment of Chronological Age of Individuals using Radiological and Ultrasonological Means. Int J Contemp Med Res. 2017;4(4):818–

21.

42. Wubneh M. Addis Ababa, Ethiopia - Africa's diplomatic capital. Cities. 2013;

43. Geremew AB, Gelagay AA, Azale T. Comprehensive knowledge on cervical cancer , attitude towards its screening and associated factors among women aged 30 – 49 years in Finote Selam town , northwest Ethiopia. 2018;1–12.

44. Washburn SL. Skeletal Age Changes in Young American Males, Analyzed from the Standpoint of Age Identification. Thomas W. McKern and T. D. Stewart. Technical Report EP-45, Environmental Protection Research Division, Quartermaster Research and Development Center, U.S. A. Am Antiq. 1958;

45. Hassan N, Noor F, Ahmad S, Fazili KM. Age of fusion of the distal radial and ulnar epiphyses from hand radiographs—A study in Kashmiri population. Sci Justice [Internet]. 2016;56(6):431–6. Available from: http://dx.doi.org/10.1016/j.scijus.2016.06.012

46. Ebeye OA, Okoro OG, Ikubor JE. Radiological assessment of age from epiphyseal fusion at the wrist and ankle in Southern Nigeria. Forensic Sci Int Reports [Internet]. 2021;3(October 2020):100164. Available from: https://doi.org/10.1016/j.fsir.2020.100164

47. Patil RC, Magi A, Mugadlimath A, Hiremath R. Age Estimation Based on Appearance of Pisiform Bone : A Radiographic Study from North-Karnataka. Indian J Forensic Community Med. 2016;3(October-December):240–4.

9. ANNEXES

9.1. Proforma - 1

The following proforma was used for collection of information obtained from the study participants, birth certificate or vaccination card and from parents or legal guardians of study subject. Thus, data including the appearance and degree of fusion of the ossification centers of the bone epiphysis were filled by the assessors after conduction of complete reading of the X-ray results in collaboration with forensic physicians and radiologists.

Study subject's preliminary particulars (to be collected from study subject and/or parents or legal guardian of the study subject).						
Study subject No.___						
Age (retrieved from documents showing proof of age e.g. birth certificate)						
Sex:	If female; pregnant or not					
Height:	Weight:					
Place of residency:						
Radiological examination						
X-ray identification number						
Date and time of X-ray taken						
Joint/bone (Left/Right)						
Different stage of epiphysial fusion						
Age (in years)	**Not appeared**	**Stage fusion (Appeared)**				
Anonymous for the raters	**0**	**1**	**2**	**3**	**4**	**5**

9.2. Proforma 2: Information sheet

Hello, my name is _____, I am one of the participants who is working on a X-ray study of hand wrist bone for evaluation of skeletal maturity on clients visiting St. Paul's Hospital Millennium Medical College and on students in Addis Ababa.

Purpose of the study – To assess the possible age at which the bones of hand wrist will appear and fuse so as to determine the chronological age of the study subject that will be selected randomly from clients visiting St. Paul's Hospital Millennium Medical College and students in Addis Ababa, Addis Ababa, Ethiopia.

Risk and benefits – The effective radiation received during each exposure will be between 0.0001-0.1 mSV.[1] Adequate precautions will be taken to avoid unnecessary X-ray exposure of subjects and as well for the working staffs by covering the non-study body regions with a protective shield. And most importantly, having a radiography of non-dominant hand, which is by nature away from

the main trunk of your body will fortunately reduce the possible radiation exposure to the rest of the body significantly. You will be benefited from participating in this study by having you a screening result given by a radiologist expert for any of the bone diseases like tumors, infections and joint abnormalities. And most importantly, this study will benefit the society when the information deducted finally shades light in providing justice for the victims. The transportations and other costs that could be expended during the study will be covered by me. Voucher cards for mobile credit will be given for encouragement purpose.

I only need a few moments of your precious time to take part in this study.

Payments for participating – You will not receive any payment for participating in this study.

Confidentiality – The information collected from this study will be kept confidential and it will only be used for research purposes. The information will be stored in a file without any personal identifiers, but a code number will be assigned to it.

Right to refusal or withdrawal – You have a full right to refuse and/or withdraw from the study at any time.

Do you have any questions?

May I begin?

9.3. Consent form

I am willing and/or allow my child (for parents/legal guardians) to participate in the study, after it has been explained to me thoroughly in a language that I understand.

Signature: _____

Name of advisor_____ signature_____ date _____

Name of investigator: _____ Signature: _____ Date: _____

Identifiers: - Study subject No. _____

This page is left empty intentionally.